

Guiding “Invisible” Laser Treatment

Optical coherence tomography and fluorescein angiography imaging may be combined with a pattern scanning delivery device to optimize micropulse laser therapy.

BY EDWARD R. THOMAS, MD

Diabetic retinopathy affects approximately one-third of patients with diabetes mellitus (DM), with duration of DM affecting the frequency of ocular involvement.¹ Diabetic macular edema (DME) is estimated to affect about 7% of patients with DM. The prevalence of DM continues to increase, and the disease is already a major cause of blindness worldwide. Early retinal changes are the first sign of significant pathology, and, when moderate disease is accompanied by clinically significant macular edema, laser photocoagulation, intravitreal anti-VEGF injections, or steroid injections are often used. Some physicians have turned away from conventional laser photocoagulation in favor of micropulse laser therapy (MPLT) to stimulate retinal cells without causing cellular destruction. As defined treatment settings have not yet been established for MPLT, I rely heavily upon fluorescein angiography (FA), optical coherence tomography (OCT), and image management software to diagnose and track disease progression in my patients.

OCULAR IMAGE MANAGEMENT

When a patient presents with suspected or confirmed diabetic retinopathy, I first acquire an understanding of the vascular lesions with FA, followed by OCT imaging. I liken OCT imaging to a pathology slide that displays all the details of the retina. Once I have these images, I upload them to the Merge Image Management Software (Merge Healthcare). This software allows me to create a permanent record of the exact treatment and area of evaluation, and it numbers the images so that I can easily track change over time (Figure 1).

TREATING WITH “INVISIBLE” MICROPULSE LASER

Traditional continuous-wave photocoagulation can result in visible burns on the macula that can spread over time. Thus, a 0.1-mm spot at the time of treatment could

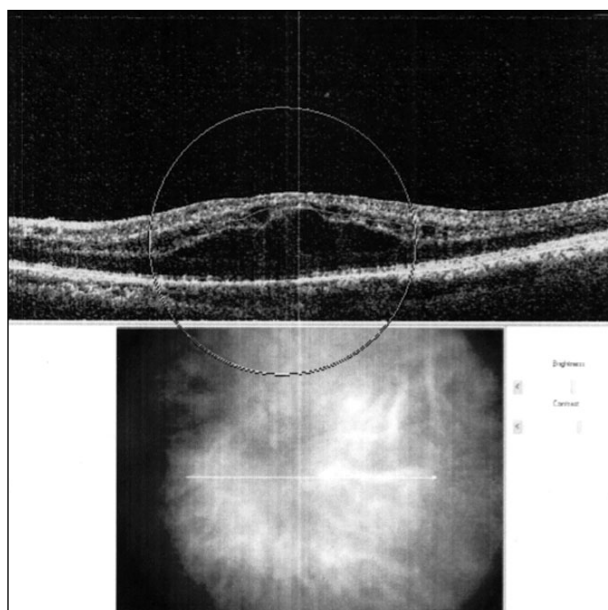


Figure 1. Merge software allows the physician to circle the exact area of interest, enabling precise comparison over time.

become a 0.5-mm spot years later, making a small defect in a patient’s vision worse. MPLT takes a traditional laser stream and chops it into a train of short, repetitive, and punctuated pulses that allow tissue to cool, preventing thermal buildup. Rather than attempting to coagulate or destroy the cells, the goal with MPLT is to stimulate the cells. This photostimulation, or “tickling,” of the retinal pigment epithelium has been shown to activate beneficial biologic and antiinflammatory factors.^{2,3}

MPLT can be challenging to perform in that a high-density laser application of very smooth, consistent, and homogeneous laser spots without any hot spots is delivered, but there is no visible indication of the laser until the reduction in edema appears weeks or months later. I find it preferable to use the IQ 577 laser (Iridex) along with the

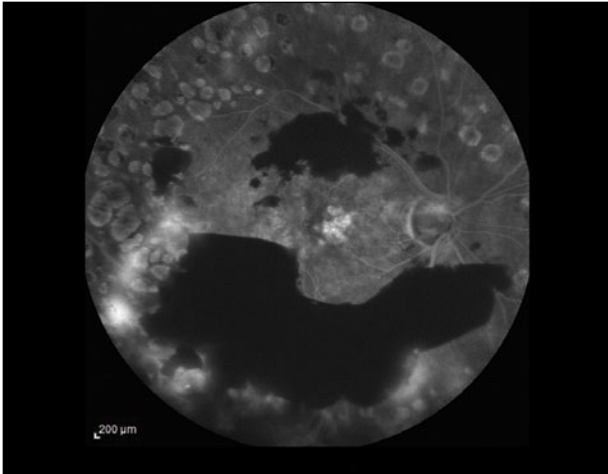


Figure 2. A fluorescein angiogram shows vitreous hemorrhage and destruction from previous laser treatment.

TxCell Scanning Laser Delivery System (Iridex) to apply MPLT. This allows me to have a high level of confidence that treatment has been delivered correctly. TxCell allows me to apply a dense, confluent laser pattern in a very rapid manner, providing predictability and control during the laser treatment even though there is no visible laser burn. After visualizing the area to be treated, I select a grid, circle, or triple arc pattern and indicate the size of the treatment area. Subthreshold laser is applied confluent, consistently, and efficiently, without the surgeon having to guess where laser spots have already been applied and where the laser should be moved next.

Three months following laser treatment, FA and OCT imaging is repeated. The Merge system marks the area of interest with a gold circle and lines up the images sequentially, allowing the user to evaluate progress. As there is no destruction of cells, MPLT can be repeated as necessary, and this is my preferred treatment plan rather than intravitreal injections. I continue to track progress and repeat treatments as necessary until the central retinal thickness decreases, edema diminishes, and there is no longer evidence of leaking blood vessels.

CASE NUMBER 1: VITREOUS HEMORRHAGE AND DIABETIC MACULAR EDEMA

A 49-year-old white man presented with a 37-year history of insulin-dependent diabetes. He was treated 10 years prior with panretinal photocoagulation (PRP), and he now presented with new complaints of blurred vision and floaters in his right eye. His most recent HbA1c hemoglobin test was 9.5%, and his visual acuity was 20/70. Imaging showed new vitreous hemorrhage and DME along with evidence of dense PRP treatment (Figures 2 and 3). Using the IQ 577 laser, the patient was treated with a laser indirect

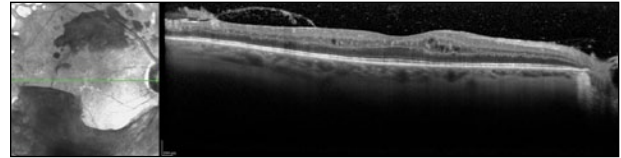


Figure 3. OCT shows clinically significant macular edema and vitreous hemorrhage before treatment.

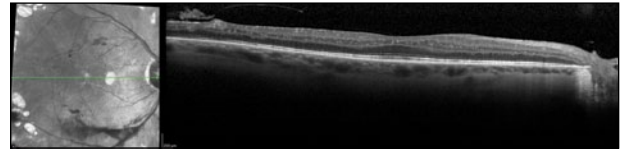


Figure 4. imaging shows greatly improved vitreous hemorrhage with evidence of micropulse laser therapy.

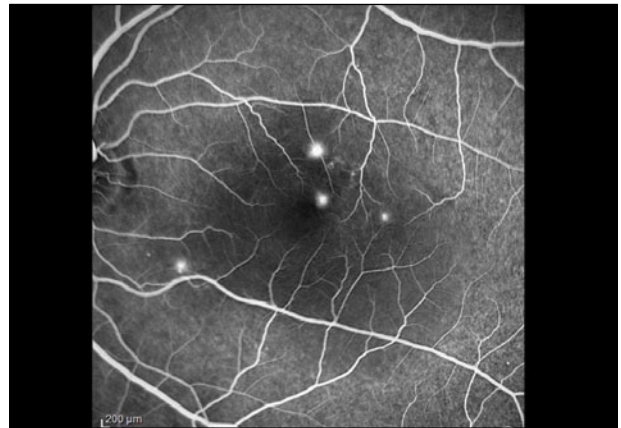


Figure 5. FA imaging shows evidence of central serous chorioretinopathy.

ophthalmoscope minipulse PRP with 20 ms duration, 400 mW power, and a 80 ms interval. This was followed by micropulse focal laser using a 200 μm spot size, 200 ms duration, 5% duty cycle, 400 mW power, and a 200 ms interval. A confluent grid was delivered, covering the entire area of edema. The patient reported that both procedures were painless. Three months after treatment, the patient had a visual acuity of 20/50, and vitreous hemorrhage and DME had improved greatly despite only modest improvement in the patient's blood sugar control (Figure 4).

CASE NUMBER 2: CENTRAL SEROUS CHORIORETINOPATHY

A 56-year-old Asian man who was taking prednisone for myasthenia gravis presented with blurred vision and 20/25 visual acuity in his left eye. Fundus examination and OCT imaging revealed central serous chorioretinopathy (Figures 5 and 6). Treatment was delayed for 3 months so the patient could taper down his oral steroids (10 mg/5 mg alternating days), allowing the fluid to resolve. After 3 months, there

(Continued on page 58)

(Continued from page 55)

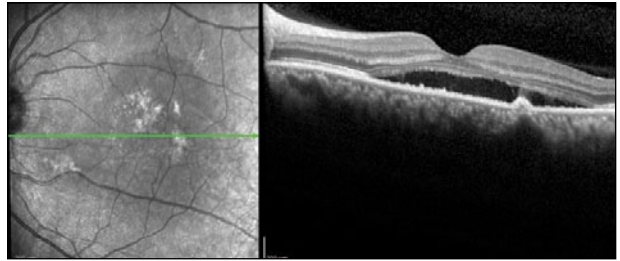


Figure 6. An OCT scan shows significant fluid beneath the fovea, evidence of central serous chorioretinopathy.

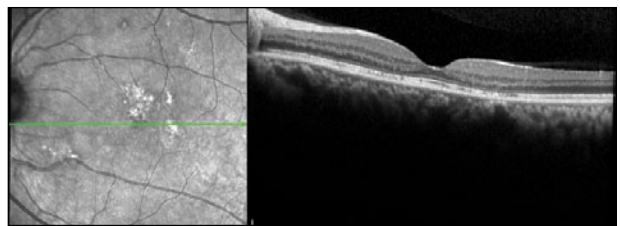


Figure 7. After MPLT, an OCT scan shows complete resolution of fluid.

was only mild improvement. After discussing his steroid regimen with his endocrinologist and determining that the patient could not go to any lower maintenance dose, the decision was made to try MPLT with 100- μ m spot size, 200-ms duration, 5% duty cycle, 240-mW power, at 200-ms intervals, delivering a confluent grid to the entire area of edema. A few weeks after the initial treatment, vision returned to 20/20, and 6 months later his macula is still dry despite being on the same prednisone dose (Figure 7).

Both of these patients will be monitored for recurrence, but neither had any discomfort or any visible laser spots in the macula. I would feel much safer repeating their treatments with MPLT, if needed, than I would have with traditional focal laser or PRP. ■

Dr. Thomas would like to acknowledge Haroon Chaudhry, MD, a retinal specialist, for his contributions to the treatment plans and methods for this article.

Edward R. Thomas, MD, practices at Ohio Eyecare Institute, a division of Premier Health in Dayton, OH, and is a clinical associate professor of surgery, Wright State University Boonshoft School of Medicine. Dr. Thomas may be reached at oheycare@gmail.com.



1. Ding J, Wong TY. Current epidemiology of diabetic retinopathy and diabetic macular edema. *Curr Diab Rep.* 2012;12(4):346-354.
2. Ogata N, Tombran-Tink J, Jo N, Mrazek D, Matsumura M. Upregulation of pigment epithelium-derived factor after laser photocoagulation. *Am J Ophthalmol.* 2001;132(3):427-429.
3. Binz N, Graham CE, Simpson K, et al. Long-term effect of therapeutic laser photocoagulation on gene expression in the eye. *FASEB J.* 2006;20(2):383-385.