

MicroPulse™ Laser Therapy and Anti-VEGF Injections for Macular Edema Associated with CRVO



Patrick Caskey, MD, is a co-founder of North Bay Vitreoretinal Consultants in Santa Rosa, Calif. He has participated in multiple landmark clinical trials, including the Macular Photocoagulation Study, the Diabetic Retinopathy Study and the Diabetes Complications and Control Study.

I've been using MicroPulse Laser Therapy (MPLT) in my practice since we replaced our aging 532-nm lasers with two IRIDEX IQ 577™ laser systems 2 years ago. The IQ 577 is a yellow-wavelength laser that can be used to treat a variety of retinal disorders. It also includes an optional module for delivering MPLT. I was intrigued by the literature on MPLT and having the new lasers in-house gave me the opportunity to personally evaluate this treatment approach.

In my early experience, the promise of MPLT — treatment efficacy without inducing thermal damage to retinal tissue — seemed too good to be true. However, I've used it in the treatment of diabetic macular edema, retinal vein occlusions, central serous chorioretinopathy and idiopathic macular telangiectasia, and generally, results have been very good. In many cases, outcomes have been superior to what I would have expected to achieve with standard focal laser, with the added benefit of no apparent collateral tissue damage. Typically, I utilize MPLT in combination with other treatments, primarily anti-VEGF or steroid injections, in an effort to target macular edema via different therapeutic avenues as well as decrease treatment burden for the patient.

I have been particularly impressed with MPLT's effectiveness against macular edema associated with central retinal vein occlusion (CRVO), a condition in which standard focal laser has been found to be of little benefit. The case described here is an example from my files.

PATIENT PRESENTATION, EXAMINATION AND INITIAL TREATMENT

The patient, a 64-year-old male with a history of systemic hypertension, became aware of decreased vision in his left eye in early February of 2012 and was referred to me Feb. 13. A fundus exam revealed increased vascular tortuosity, scattered posterior pole hemorrhages and moderately severe macular edema. No cotton-wool spots were present. Fluorescein

angiography demonstrated hypertensive arteriovenous crossing changes with capillary nonperfusion. Central retinal thickness (CRT) measured 870 μm on SDOCT (Spectralis, Heidelberg) (See Fig. 1). Uncorrected visual acuity (VA) was 20/150 (pinhole 20/100 -1). The patient was treated with intravitreal bevacizumab and scheduled to return in 1 month.

Fundus evaluation 1 month later showed reduction of the hemorrhages and vascular tortuosity. Intraocular pressure was 16 mmHg, and VA had improved to 20/25 +1. CRT had also improved, but still measured 490 μm on SDOCT, so a second bevacizumab injection was administered.

"Repeat treatments and treating through the fovea can be done safely using MPLT."

The patient returned for follow-up about 1 month later. The hemorrhages in the left eye had decreased further, and SDOCT revealed an additional reduction in CRT to 342 μm . Uncorrected vision was 20/70 +/-1 (pinhole 20/20 -2). The patient received a third anti-VEGF injection.

By the next follow-up visit 6 weeks later, the patient's macular edema had worsened. Average CRT on SDOCT had increased to 584 μm , and uncorrected VA had declined to 20/70 -2 (See Fig. 2). At this point, other treatment options were discussed with the patient and he elected to undergo MPLT.

MICROPULSE LASER THERAPY

The patient underwent MPLT June 5. Prior to the treatment, I performed a test burn in an area outside the macula using the IRIDEX IQ 577 laser in continuous-wave mode. At a 100- μm spot size and 200-ms exposure duration, a barely visible whitening of the tissue occurred at a power of 80 mW. Based on the MPLT parameters pioneered by others as well as my own experience, I switched the laser to MicroPulse mode and delivered treatment using twice the power determined from the test burn (in this case, 160 mW), a 100- μm spot size, a 200-ms duration and a 5% duty cycle. I placed 357 high-density, confluent applications over the entire edematous area. For both the test burn and the actual treatment I used the Area Centralis lens (Volk Optical). I have found this lens to provide a sharp image as well as a favorable balance between field of

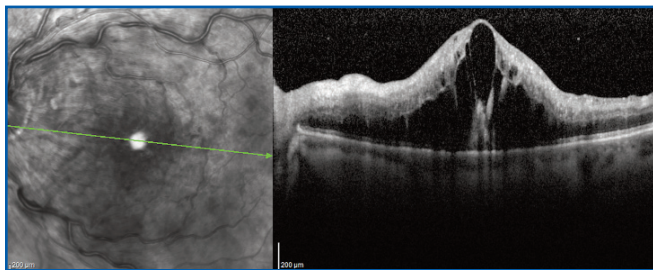


Figure 1. Pretreatment: VA 20/150 | CRT 870 μ m. Clinical exam revealed prominent cystoid macular edema.

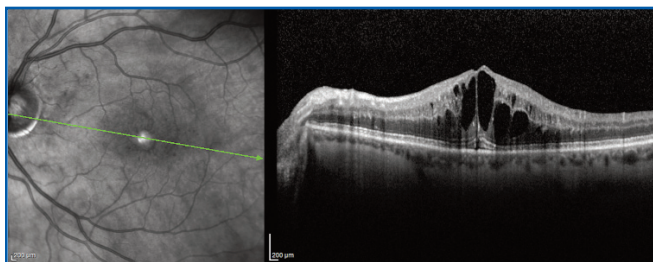


Figure 2. 6 weeks post third anti-VEGF treatment / Pre MPLT: VA 20/70-2 | CRT 584 μ m. Recurrent macular edema noted.

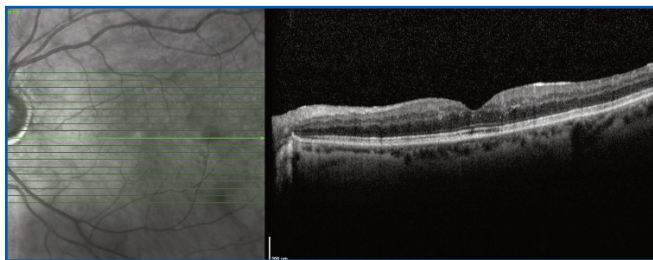


Figure 3. Approximately 5 months post MPLT: VA 20/40+2 | CRT 261 μ m. No macular edema observed on clinical exam.

view and clarity, which is important for accurately directing the laser to the areas of edema. The patient was comfortable during treatment and was instructed to return for follow-up on Aug. 28.

At the Aug. 28 postoperative visit, only slight macular edema remained. Average CRT on SDOCT was 289 μ m. Uncorrected VA had improved to 20/50 +/-1. The patient's final visit to my office was on Oct. 29, 2012, at which time no macular edema was observable on clinical exam. The average CRT on SDOCT was 261 μ m. Uncorrected VA was 20/40 +2 (See Fig. 3). The patient has remained stable and has not required further treatment.

PRACTICE LOGISTICS

MPLT is remarkably easy to learn. Any vitreoretinal specialist familiar with the use of continuous-wave

TABLE 1. TREATMENT PARAMETERS

IRIDEX IQ 577 for MPLT of macular edema associated with central retinal vein occlusion

- Wavelength: 577 nm
- Spot size on slit lamp adapter: 100 μ m
- Contact lens: Area Centralis (Volk)
- Power: 160 mW (based on 2x the power determined from a continuous-wave test burn using a 100- μ m spot)
- Exposure duration: 200 ms
- Duty cycle: 5%
- MicroPulse delivery: High-density, confluent applications placed over the edematous area

focal laser should be able to use the treatment without difficulty once he or she becomes familiar with the rationale guiding the test burn and the parameters for delivering a confluent and contiguous treatment. Even though the absence of visible laser burns (to serve as treatment endpoints) may seem counter-intuitive at first, confidence in the efficacy and safety achieved with MPLT builds after just a few cases. Repeat treatments and treating through the fovea and parafoveal tissues, which may be contraindicated with standard laser because of thermal damage, can be done safely using the MPLT treatment parameters as described.

The IRIDEX IQ 577 laser system itself is efficient and ergonomic. We've been able to enhance the laser's utility by installing it to deliver treatments in an exam lane. The unit is small, which enables it to be mounted on a swing arm. Our exam chair allows the patient to lie down or sit at the slit lamp, and the laser mode can be easily changed with the touchscreen. Utilizing MPLT in the exam lane has streamlined our office flow because patients don't have to move in and out of a separate laser room.

Adopting this unique therapy was a leap of faith for me initially because, as a skeptic by nature, I had concerns whether I could really be helping patients by using subthreshold treatment. The answer turned out to be an emphatic "yes" in my experience, and the "icing on the cake" has been treatment efficacy without concurrent thermal collateral tissue destruction. ■

Treatment techniques and opinions presented in this case report are those of the author. IRIDEX assumes no responsibility for patient treatment and outcome. IRIDEX, IRIDEX logo are registered trademarks, and MicroPulse is a trademark of IRIDEX Corporation.